

# Junctional ectopic tachycardia as an AVNRT catheter ablation complication in children

Gabriel Cismaru<sup>\*</sup>, Gelu Simu, Mihai Puiu, Gabriel Gusetu, Dana Pop, Dumitru Zdrenghea, Radu Rosu



Use your smartphone to scan this QR code and download this article

## ABSTRACT

Junctional ectopic tachycardia (JET) occurs postoperatively or after catheter ablation in the region of Koch's triangle. The post-ablation incidence of JET reported in the medical literature is very low. We report the case of a 13-year-old female patient who underwent catheter ablation of the slow pathway for atrioventricular node reentrant tachycardia and subsequently developed JET. An accelerated automatic ectopic focus was found in the atrioventricular junction area due to radiofrequency applications. Treatment with metoprolol, ivabradine, propafenone, and amiodarone was ineffective in stopping the arrhythmia. However, JET resolved within 30 days without other antiarrhythmic drugs.

**Key words:** AVNRT, atrioventricular node reentrant tachycardia, JET, junctional ectopic tachycardia

## INTRODUCTION

Junctional ectopic tachycardia (JET) occurs in children due to increased automatism in two main clinical settings: (1) near the atrioventricular junction in the initial postoperative phase<sup>1</sup> and (2) in the region of Koch's triangle after catheter ablation. It has been associated with ischemia, stretch, and direct damage to the heart's atrioventricular (AV) conduction tissue during radiofrequency (RF) application. JET appears on a 12-lead electrocardiogram (ECG) as a narrow QRS tachycardia without detectable P waves<sup>2</sup>. It can be regular or irregular. It is focal, and unlike AV nodal reentry and AV reentry supraventricular arrhythmias, it does not involve a reentry circuit. It might have 1:1 retrograde atrial conduction or AV dissociation.

The post-ablation incidence of symptomatic JET reported in the medical literature is very low (3 cases per 37,541 [0.008%]) and is reported exclusively in pediatric patients<sup>3</sup>.

We report the case of a 13-year-old female patient who underwent catheter ablation of the slow pathway for atrioventricular node reentrant tachycardia (AVNRT) and subsequently developed JET. An accelerated automatic ectopic focus was found in the AV junction area due to RF applications.

## CASE PRESENTATION

A 13-year-old female patient was admitted to the Cardiology Department for palpitations that started five years ago in 2018. The palpitations had a fast rhythm (190 bpm), regular character, variable duration (5 – 15 minutes) with spontaneous remission,

and appeared during effort or rest. In 2022, she had weekly palpitation episodes. At presentation, she had a heart rate of 80 bpm and blood pressure of 120/70 mmHg without any sign of left or right heart failure. Her ECG showed a normal sinus rhythm with a normal PR interval (**Figure 1**). Her echocardiography was also normal. Due to the recurring nature of the arrhythmia, an electrophysiological study was performed using the Carto 3 Biosense Webster system without X-ray exposure<sup>4</sup>. An anatomical map of the right atrium was created (**Figure 2**), and the His bundle was marked. We identified fast and slow nodal pathways, and RF ablated the slow pathway in the posteroseptal area. Due to multiple applications at the slow pathway level (**Figure 2**) without its complete disappearance, a JET occurred with a heart rate of 125 – 130 bpm. The tachycardia became incessant after more applications to the region. Vagal maneuvers were ineffective in stopping JET. In the first 24 hours post-ablation, the patient received intravenous (i.v.; 10 mg) and oral (100 mg) metoprolol, ivabradine (10 mg), i.v. propafenone (140 mg), and i.v. amiodarone (300 mg). However, her arrhythmia remained incessant (24/24 hours). On the second day, she received amiodarone and metoprolol and experienced short sinus rhythm episodes. On the third day, she stayed 16 hours in sinus rhythm and 8 hours in JET. Before discharge, she performed a stress test stopped at 125 W without any JET episode. She was discharged with amiodarone and metoprolol. After 30 days, both drugs were interrupted without any arrhythmia recurrence.

5th Department of Internal Medicine, Cardiology-Rehabilitation, "Iuliu Hatieganu" University of Medicine and Pharmacy Cluj-Napoca, Romania

## Correspondence

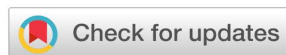**Gabriel Cismaru**, 5th Department of Internal Medicine, Cardiology-Rehabilitation, "Iuliu Hatieganu" University of Medicine and Pharmacy Cluj-Napoca, Romania

Email: gabi\_cismaru@yahoo.com

## History

- Received: Dec 12, 2022
- Accepted: Feb 15, 2023
- Published: Feb 28, 2023

DOI : 10.15419/bmrat.v10i2.793

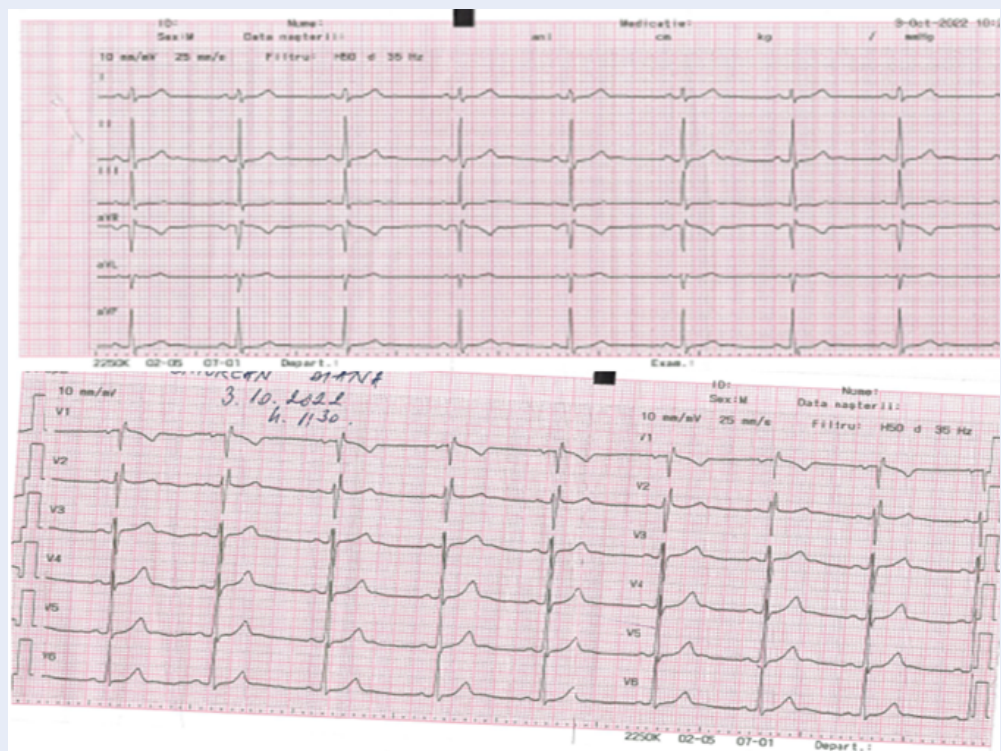


## Copyright

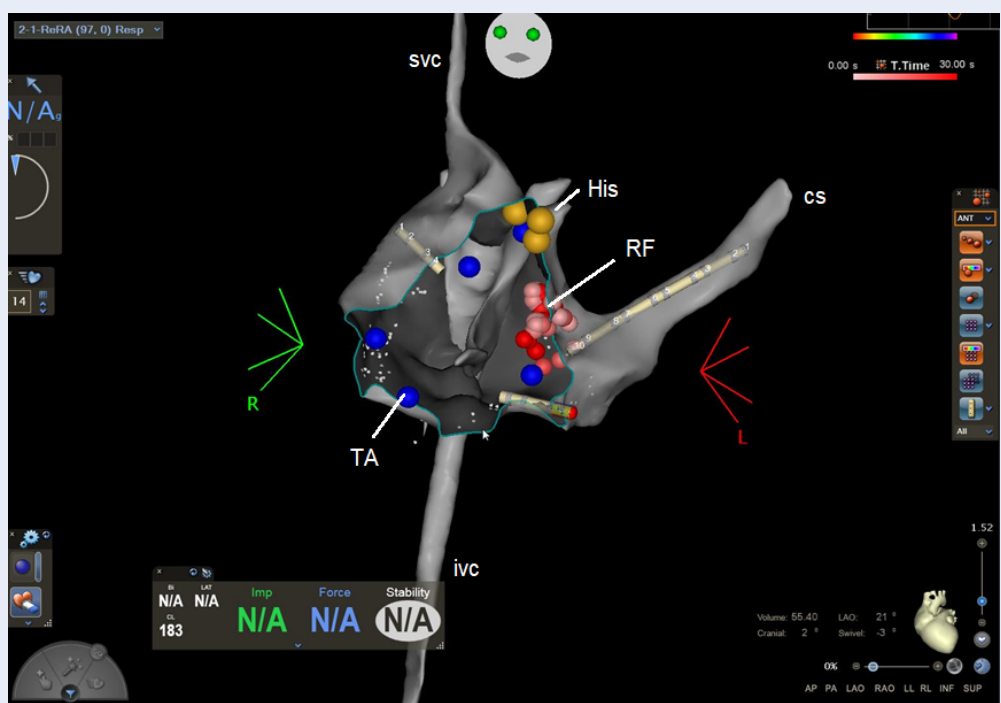
© Biomedpress. This is an open-access article distributed under the terms of the Creative Commons Attribution 4.0 International license.



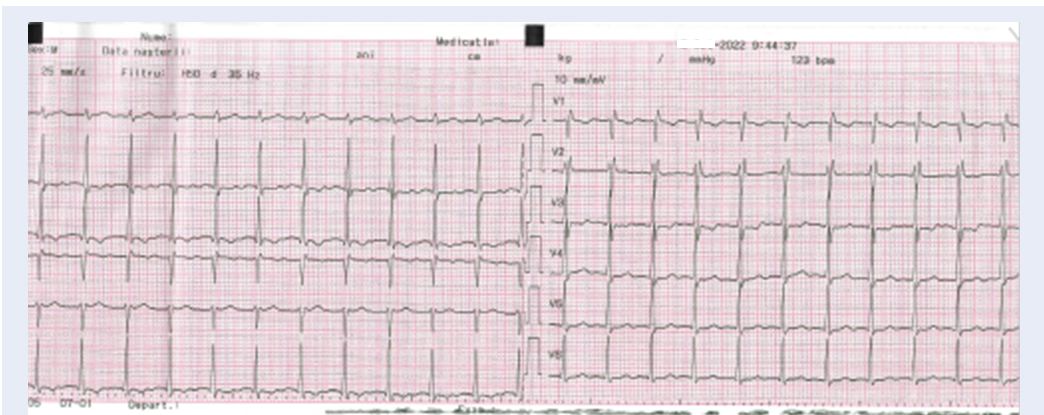
**Cite this article :** Cismaru G, Simu G, Puiu M, Gusetu G, Pop D, Zdrenghea D, Rosu R. **Junctional ectopic tachycardia as an AVNRT catheter ablation complication in children.** *Biomed. Res. Ther.*; 2023, 10(2):5545-5549.



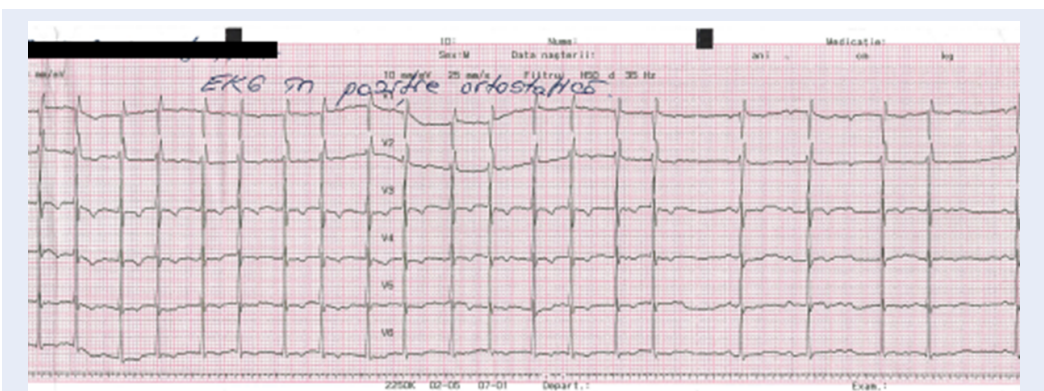
**Figure 1:** The 12-lead ECG before catheter ablation shows sinus rhythm with a normal PR interval.



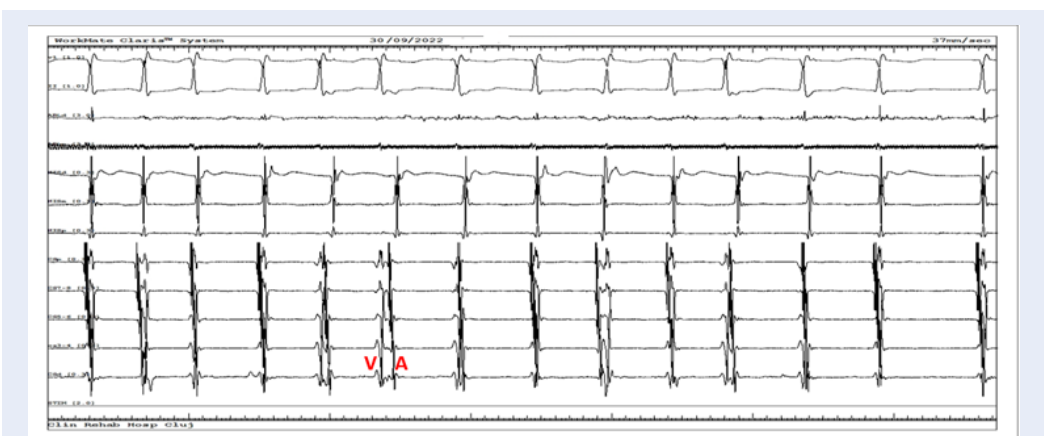**Figure 2:** An anatomical map of the right atrium. Blue dots delimit the tricuspid annulus (TA) on the right atrium’s anterior part. Yellow dots mark the position of the His bundle (His). Red dots mark the RF ablation points placed at the slow pathway level. Key: CS, coronary sinus; IVC, inferior vena cava; SVC, superior vena cava.



**Figure 3:** The 12-lead ECG after catheter ablation for AVNRT shows a narrow QRS tachycardia. Intracardiac electrograms with His bundle preceding both ventricular and atrial electrograms and atrial entrainment (not shown) confirmed JET.



**Figure 4:** The 12-lead ECG shows a JET episode that stops and is followed by normal sinus rhythm.



**Figure 5:** An intracardiac electrograms during JET. The image shows junctional tachycardia at the end of the procedure, with a 470 ms cycle length, that starts and stops spontaneously, lasting 10–90 seconds. A and V potentials are marked on the coronary sinus (Cs) catheter electrogram.

## DISCUSSION AND CONCLUSION

Catheter ablation is a successful therapeutic option for treating AVERT. However, arrhythmic complications such as complete AV block or JET are possible. These are distinct from the junctional rhythm commonly produced during RF applications in the posteroseptal region of Koch's triangle, which is a sign of success during ablation for AVNRT<sup>5</sup>.

Another possible AVNRT ablation complication can be impaired conduction through the AV node. Complete AV block is an uncommon AVNRT catheter ablation complication. Most cases are transient and occur during RF application. In this case, AV conduction was temporarily impaired due to edema caused by the RF current in the tissue around the AV node. AV conduction recovers following tissue edema resolution. However, persistent high-degree AV block is believed to result from permanent tissue damage with necrosis caused by the ablation. The AV block mostly occurs in the early phase after ablation. Delayed AV block has been seen in very few cases. Brembilla *et al.* reported three patients with complete AV block that developed 1–3 days after catheter ablation and further resolved with one-to-one AV conduction. Fenelon *et al.* described a patient with a delayed Mobitz I second-degree AV block at rest and Mobitz II block during physical activity three months after catheter ablation. Williamson *et al.* described three cases of complete AV block developing 36 – 72 hours after catheter ablation. Several studies reported a positive effect of anti-inflammatory drugs in cases with AV block following catheter ablation of the slow pathway. Parwani *et al.* described a case of third-degree AV block that occurred three days after catheter ablation, which was further treated with i.v. prednisolone (250 mg) continued with oral prednisone and ibuprofen (600 mg) daily. At the 12-month follow-up, they described a normal PR interval during a 24-hour Holter ECG. Hoshiyama *et al.* described a case of complete AV block after catheter ablation of the slow pathway. Their patient was treated with colchicine (1 mg/kg) with complete resolution of the AV block after seven days.

In JET, increased automaticity is believed to be the primary cause of arrhythmia<sup>5</sup>. Other mechanisms were also implicated, such as triggered activity, calcium overload, and increased inflammation with high tumor necrosis factor-alpha and interleukin 1-beta levels<sup>6</sup>. JET arising post-surgery<sup>7</sup> and post-ablation may have a similar mechanism since RF applications in the region of Koch's triangle may cause localized

micro-hemorrhages and coagulation necrosis, similar to those produced during surgery or electrocauterization<sup>8</sup>. In addition, Zahn *et al.* and Thibault *et al.* showed through experimental studies that introducing ice or warm water into the region of Koch's triangle near its anteriormost point induced an active junctional rhythm<sup>9-11</sup>.

While 37,541 AVNRT ablation cases have been examined in the literature<sup>3</sup>, only three occurrences of JET, all in pediatric patients, were documented, providing a reported incidence of 0.008%. These three patients required therapeutic intervention (medication or repeat ablation), which is likely why they were explicitly mentioned. It is conceivable that transitory JET forms that disappear soon after ablation go unreported.

The medical literature contains limited information about JET. In most instances, JET appears to cease within days following catheter ablation for AVNRT. Nevertheless, its brief duration renders it of minimal clinical significance. However, medical therapy should be recommended when JET persists for several hours over several days and is associated with symptoms. JET is treated using beta blockers, flecainide, and anti-inflammatory drugs, including steroids. When symptoms persist after drug administration, the junctional region may be re-ablated. Since cryoablation requires a gentler energy type from the tissue necrosis perspective and greater lesion reversibility when not using extremely low temperatures, it remains the treatment of choice for JET resistant to antiarrhythmic drugs<sup>12</sup>.

AVNRT alternately using two slow pathways cannot be excluded in **Figures 3, 4 and 5** since the ECG shows consecutive short and long cycles with constant cycle lengths. However, this tachycardia began and terminated spontaneously, was repetitive, and lasted seconds to minutes.

## ABBREVIATIONS

AVNRT: atrio-ventricular node reentrant tachycardia, JET: junctional ectopic tachycardia.

## ACKNOWLEDGMENTS

None.

## AUTHOR'S CONTRIBUTIONS

All author equally contributed to this work. All authors read and approved the final manuscript.

## FUNDING

None.

## AVAILABILITY OF DATA AND MATERIALS

The data used and analyzed during the case report are available from the corresponding author upon reasonable request.

## ETHICS APPROVAL AND CONSENT TO PARTICIPATE

Informed written consent was obtained from the patient's mother to publish this case report and any accompanying medical images.

## CONSENT FOR PUBLICATION

Not applicable.

## COMPETING INTERESTS

The authors declare that they have no competing interests.

## REFERENCES

1. Catton KG, Peterson JK. Junctional Ectopic Tachycardia: Recognition and Modern Management Strategies. *Critical Care Nurse*. 2020;40(1):46–55. PMID: 32006036. Available from: [10.4037/ccn2020793](https://doi.org/10.4037/ccn2020793).
2. Alasti M, Mirzaee S, Machado C, Healy S, Bittinger L, Adam D. Junctional ectopic tachycardia (JET). *Journal of Arrhythmia*. 2020;36(5):837–44. PMID: 33024461. Available from: [10.1002/joa3.12410](https://doi.org/10.1002/joa3.12410).
3. Liu CF, Ip JE, Lin AC, Lerman BB. Mechanistic heterogeneity of junctional ectopic tachycardia in adults. *Pacing and Clinical Electrophysiology*. 2013;36(1):e7–10. PMID: 21954877. Available from: [10.1111/j.1540-8159.2011.03214.x](https://doi.org/10.1111/j.1540-8159.2011.03214.x).
4. Cismaru G, Muresan L, Puiu M, Rosu R, Gusetu G, Pop D, et al. Ablation of a left-sided accessory pathway with near-zero fluoroscopy in a 9-year-old boy. *Oxford Medical Case Reports*. 2017;2017(9):omx052. PMID: 28928979. Available from: [10.1093/omcr/omx052](https://doi.org/10.1093/omcr/omx052).
5. Poret P, Leclercq C, Gras D, Mansour H, Fauchier L, Daubert C. Junctional rhythm during slow pathway radiofrequency ablation in patients with atrioventricular nodal reentrant tachycardia: beat-to-beat analysis and its prognostic value in relation to electrophysiologic and anatomic parameters. *Journal of Cardiovascular Electrophysiology*. 2000;11(4):405–12. PMID: 10809493. Available from: [10.1111/j.1540-8167.2000.tb00335.x](https://doi.org/10.1111/j.1540-8167.2000.tb00335.x).
6. Zahn A. Experimentelle Untersuchungen über Reizbildung und Reizleitung im atrioventricularknoten. *Pflüger, Arch*. 1913;151(151):247–78. Available from: [10.1007/BF01705202](https://doi.org/10.1007/BF01705202).
7. Thibault B, De Bakker JMT, Hocini M, Loh P, Wittkampf FHM, Janse MJ: origin of heat-induced accelerated junctional rhythm. *Journal of Cardiovascular Electrophysiology*. 1998;9:631–41. PMID: 9654230. Available from: [10.1111/j.1540-8167.1998.tb00946.x](https://doi.org/10.1111/j.1540-8167.1998.tb00946.x).
8. Ruder MA, Davis JC, Eldar M, Abbott JA, Griffin JC, Seger JJ. Clinical and electrophysiologic characterization of automatic junctional tachycardia in adults. *Circulation*. 1986;73(5):930–7. PMID: 3698238. Available from: [10.1161/01.CIR.73.5.930](https://doi.org/10.1161/01.CIR.73.5.930).
9. Sasikumar N, Kumar RK, Balaji S. Diagnosis and management of junctional ectopic tachycardia in children. *Annals of Pediatric Cardiology*. 2021;14(3):372–81. PMID: 34667411. Available from: [10.4103/apc.apc\\_35\\_21](https://doi.org/10.4103/apc.apc_35_21).
10. Huang SK, Bharati S, Graham AR, Lev M, Marcus FI, Odell RC. Closed chest catheter desiccation of the atrioventricular junction using radiofrequency energy - a new method of catheter ablation. *Journal of the American College of Cardiology*. 1987;9(2):349–58. PMID: 3805526. Available from: [10.1016/S0735-1097\(87\)80388-1](https://doi.org/10.1016/S0735-1097(87)80388-1).
11. Kusterer N, Morales G, Butt M, Darrat Y, Parrott K, Ogunbayo G. Junctional ectopic rhythm after AVNRT ablation: an underrecognized complication. *Pacing and Clinical Electrophysiology*. 2018;41(2):182–93. PMID: 29266438. Available from: [10.1111/pace.13260](https://doi.org/10.1111/pace.13260).
12. Garson A, Gillette PC. Junctional ectopic tachycardia in children: electrocardiography, electrophysiology and pharmacologic response. *The American Journal of Cardiology*. 1979;44(2):298–302. PMID: 463767. Available from: [10.1016/0002-9149\(79\)90320-5](https://doi.org/10.1016/0002-9149(79)90320-5).